

# Rare Case of Liesegang Rings in Cystic Lesion of Left Ectopic Kidney: A Histopathological Perspective

DINISHA EINSTIEN<sup>1</sup>, SRUTHI PALLEKONDA<sup>2</sup>, RESHMI GOPAL<sup>3</sup>, RAJALAKSHMI VAIDYANATHAN<sup>4</sup>

CC BY-NC-ND

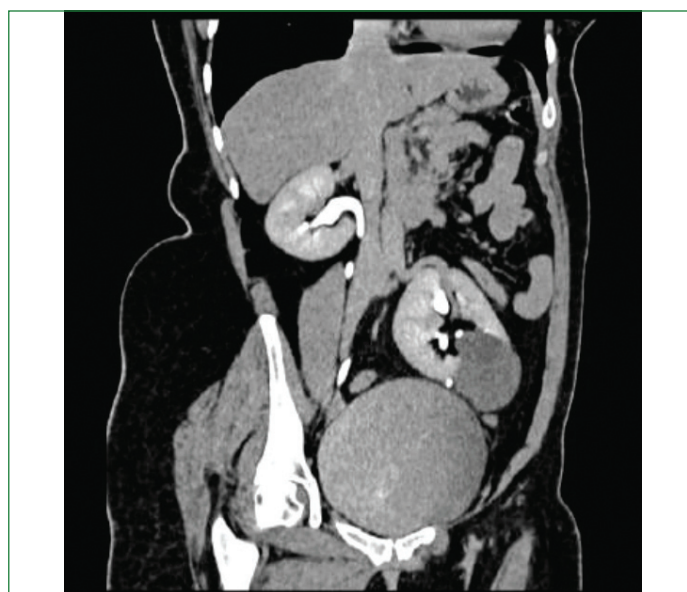## ABSTRACT

Ectopic kidneys are a rare congenital anomaly where the kidney is located outside its normal position, and renal cysts in these ectopic kidneys are even more uncommon. The authors report a unique case of a left ectopic kidney with a cystic lesion containing Liesegang rings, a rare histopathological finding. A 47-year-old female presented with intermittent abdominal pain for about two months and was found to have an abnormal renal position on imaging studies. Further investigation revealed a left ectopic kidney with a cystic mass. Surgical excision of the cyst was performed, and histopathological examination showed characteristic concentric calcifications known as Liesegang Rings (LR). These structures are typically associated with chronic inflammation, cysts, fibrotic tissue, haemorrhagic zones, necrotic areas and fluids, but they are rarely reported in renal cysts, especially in ectopic kidneys. While analysing kidney tissue or cytological specimens, it is crucial to consider their presence, as they can closely mimic various organic and inorganic substances, parasites and malignancies, posing a challenge for accurate diagnosis.

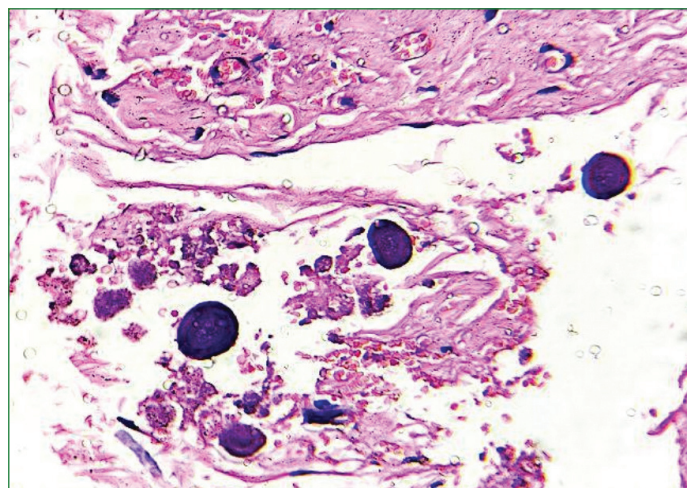
**Keywords:** Chronic inflammation, Concentric calcification, Histopathology, Parasites, Renal cyst

## CASE REPORT

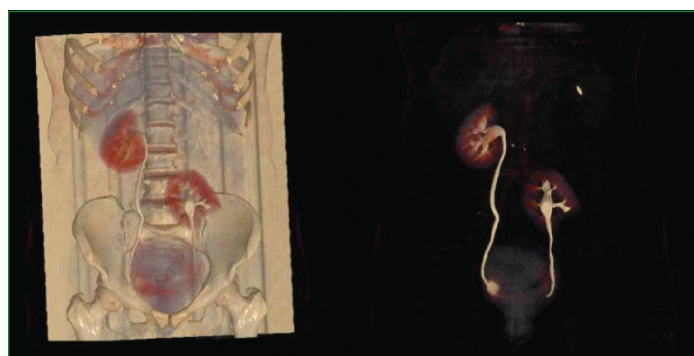
A 47-year-old female presented with intermittent abdominal pain for about two months, accompanied by intermittent vaginal bleeding. There was no significant past or medical history. The clinical diagnosis was abnormal uterine bleeding. Computed Tomography (CT) imaging revealed a thickened endometrium and an incidental left ectopic kidney with a large minimally complex parapelvic cyst measuring 4.7×4.5×5.2 cm, which had a few non enhancing thin internal septations and subtle wall calcifications [Table/Fig-1,2]. Hence, a provisional diagnosis of endometrial hyperplasia, left ectopic kidney, and parapelvic cyst (Bosniak II) was made. A left ectopic kidney cystectomy was performed, along with total abdominal hysterectomy and bilateral salpingo-oophorectomy. The specimen was received at the Department of Pathology. Grossly, the received renal cyst wall was a single grey-white soft tissue bit measuring 6×0.8 cm. Microscopic sections showed a vascularised fibrocollagenous cyst wall, which was focally lined by cuboidal cells. The cyst wall was infiltrated by lymphocytes, with occasional tubular structures lined by cuboidal cells filled with eosinophilic material. Multiple basophilic spherules (Liesegang rings) were also observed [Table/Fig-3]. This was an unexpected finding. Histochemical stains, including Masson's trichrome, Periodic Acid-Schiff (PAS) and Perl's stain, were performed for characterisation. Masson's trichrome and PAS stains highlighted the Liesegang rings, whereas they were



[Table/Fig-2]: CT urogram coronal section showing non enhancing cyst in lower part of ectopic left kidney.

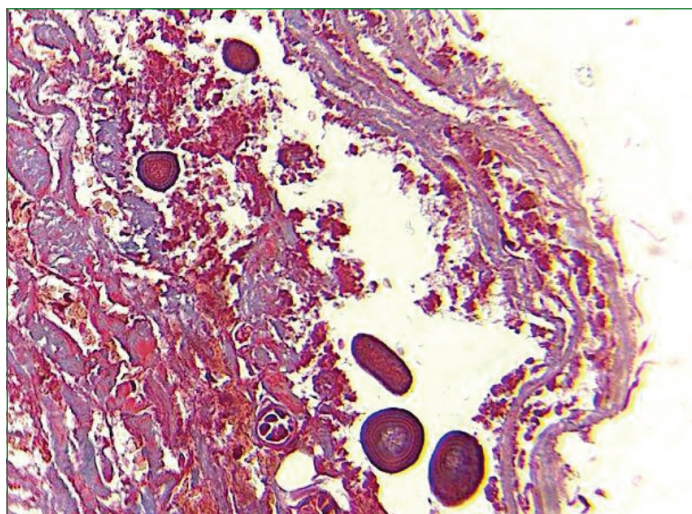


[Table/Fig-3]: Liesegang rings observed in cyst wall (H&E, 400x).

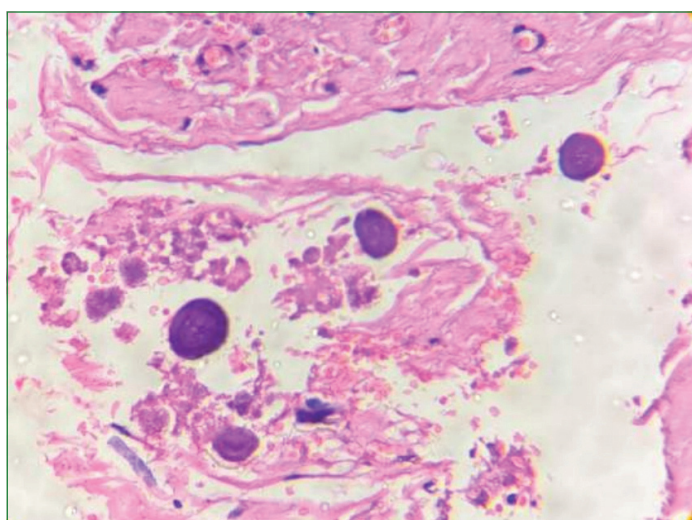


[Table/Fig-1]: Maximum Intensity Projection (MIP) of Three Dimensional (3D)-CT urogram showing defect in lower pole of ectopic left kidney representing non enhancing cyst.

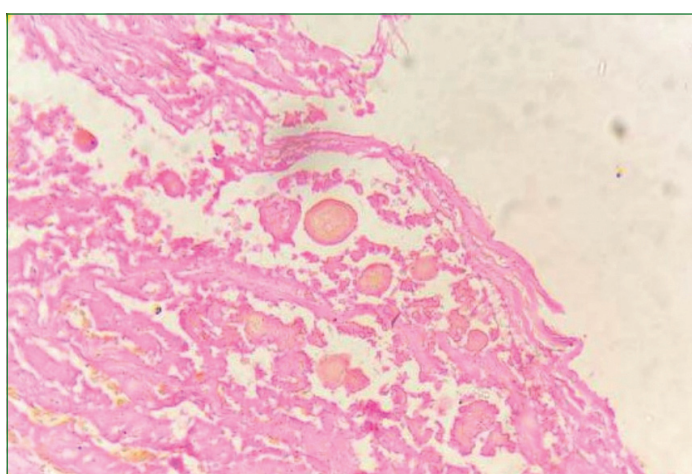
negative for iron (Perl's) stain [Table/Fig-4-6]. The final diagnosis was an ectopic kidney cyst wall, a simple renal cyst. These cases do not require further treatment, and the patient is doing well on follow-up.



[Table/Fig-4]: Liesegang rings as observed using Masson's trichrome stain, with attenuation of the concentric rings (Masson's trichrome stain, 400x).



[Table/Fig-5]: Liesegang rings observed (PAS, 400x).



[Table/Fig-6]: Liesegang rings negative for iron (Perl's stain, 400x).

## DISCUSSION

In 1896, the German chemist Raphael E. Liesegang first described the phenomenon, noting the formation of concentric, laminated rings created in-vitro by the periodic precipitation of specific chemicals around a central point in colloidal gels. Liesegang Rings (LR) are rare pathological findings that can present diagnostic challenges for pathologists [1]. LRs form through the periodic

precipitation of organic substances from a supersaturated solution within the fluid contents of cystic structures. Under transmission electron microscopy, they exhibit an amorphous, electron-dense core surrounded by fibrillary, lucent concentric rings. Electron probe microanalysis reveals no significant energy peaks, and X-ray diffraction does not show distinct diffraction patterns [2]. They are benign, lamellar structures characterised by radial striations and a central amorphous core, typically found in cysts, fibrotic tissue, haemorrhagic zones, and inflammatory processes in necrotic areas and fluids [3]. They can be confused with various parasites, algae, calcifications, corpora amyloacea, psammoma bodies, hyaline globules of adenoid cystic carcinoma, collagenous spherulosis, Michaelis-Gutmann bodies, and the spheroid type of amyloid [1,2]. They have also been mistaken for the ova, larvae, or adults of the giant kidney worm, *Dioctophyma renale* [4]. Recent reports have also documented these in xanthogranulomatous pyelonephritis [5] and malignant tumours, including cystic renal cell carcinoma [1], endometrioid ovarian carcinoma and medullary thyroid carcinoma [6].

They are best observed using Papanicolaou, haematoxylin-eosin, Masson's trichrome, Acid-fast Bacilli and Gram stains, all of which enhance the concentrically laminated morphology of these structures [2]. Immunohistochemical and histochemical stains for calcium (von Kossa), iron, mucopolysaccharides, amyloid, glycogen, keratin and epithelial membrane antigen are negative [7]. Radiologically, LR can mimic the appearance of a stone, parasite, or even a tumour. Vizcaino JR et al., reported a case of a pseudotumor of the renal pelvis: Liesegang rings mimicking a solid neoplasm of the renal pelvis [8], while Petrescu A et al., reported a new case of a renal inflammatory myofibroblastic tumour with LR rings [9]. Pegas KL et al., reported Liesegang rings in xanthogranulomatous pyelonephritis [5]. The present case was not associated with any neoplasm; it was a simple cyst containing LR rings, similar to the case reported by Bhat SP et al., whereas Wood A et al., observed a benign renal cyst containing Liesegang rings mimicking renal cell carcinoma [1,2]. Despite being known for centuries, these structures are seldom encountered in routine histopathology practice. A systematic literature search by Naresh Bharti J et al., identified a total of 22 records (26 cases) diagnosed in the kidney until 2022 [3]. This highlights the rarity of the case. Although LR is a relatively rare entity, it has been primarily associated with benign conditions and holds no clinical significance. While analysing kidney tissue or cytological specimens, it is crucial to consider their presence, as they can closely mimic various organic and inorganic substances, parasites and malignancies, posing a challenge for accurate diagnosis.

## CONCLUSION(S)

The present case provides valuable insights and highlights the need for pathologists and clinicians to be aware of atypical patterns that may offer clues to underlying pathophysiological processes. Awareness of the Liesegang phenomenon within cystic lesions will decrease the possibility of erroneous misdiagnosis as another type of pathological process.

## REFERENCES

- [1] Wood A, O'Donnell M, Casado A. A benign renal cyst containing liesegang rings mimicking a renal cell carcinoma: a case report. *Curr Urol*. 2013;7(1):37-39.
- [2] Bhat SP, Prasad KH, Ravinder P, Hegde P. Liesegang rings: An unusual mimicker in renal cyst. *Int J Health Allied Sci*. 2013;2(2):139-40.
- [3] Naresh Bharti J, Bharti S, Singh Nigam J. Liesegang rings in kidney diseases- a systematic review. *Cur Med Imaging*. 2024;20. Doi: 10.2174/1573405620666230817094600.
- [4] Tuur SM, Nelson AM, Gibson DW, Neafie RC, Johnson FB, Mostofi FK, et al. Liesegang rings in tissue. How to distinguish Liesegang rings from the giant kidney worm. *Dioctophymarenale*. *Am J Surg Pathol*. 1987;11:598-605.

- [5] Pegas KL, Edelweiss MI, Cambuzzi E, Zettler CG. Liesegang rings in xanthogranulomatous pyelonephritis: A case report. *Patholog Res Int.* 2010;2010(1):602523.
- [6] Sancheti S, Jain S. Liesegang rings: Extremely rare structures in malignant lesions. *Int J Surg Pathol.* 2018;26(1):39-40.
- [7] Kumar N, Jain S. Liesegang rings in cytologic samples accompanied by calcium oxalate-like crystals. A report of three cases. *Acta Cytol.* 2000;44(3):429-32.
- [8] Vizcaino JR, Macedo-Dias JA, Teixeira-de-Sousa JM, Silva RM, Carpenter S. Pseudotumour of renal pelvis: Liesegang rings mimicking a solid neoplasm of the renal pelvis. *Histopathology.* 2005;47(1):115-17.
- [9] Petrescu A, Berdan G, Hulea I, Gaitanidis R, Ambert V, Jinga V, et al. Renal inflammatory myofibroblastic tumour- A new case report. *Rom J Morphol Embryol.* 2007;48(4):437-42.

**PARTICULARS OF CONTRIBUTORS:**

1. Associate Professor, Department of Pathology, Panimalar Medical College Hospital and Research Institute, Chennai, Tamil Nadu, India.
2. Assistant Professor, Department of Pathology, Panimalar Medical College Hospital and Research Institute, Chennai, Tamil Nadu, India.
3. Senior Resident, Department of Pathology, Panimalar Medical College Hospital and Research Institute, Chennai, Tamil Nadu, India.
4. Professor and Head, Department of Pathology, Panimalar Medical College Hospital and Research Institute, Chennai, Tamil Nadu, India.

**NAME, ADDRESS, E-MAIL ID OF THE CORRESPONDING AUTHOR:**

Dr. Dinisha Einstien,  
Associate Professor, Department of Pathology, Panimalar Medical College Hospital  
and Research Institute, Outer Ring Road, Varadharajapuram,  
Chennai-600123, Tamil Nadu, India.  
E-mail: dinieins2010@gmail.com

**PLAGIARISM CHECKING METHODS:** [Jain H et al.]

- Plagiarism X-checker: Aug 27, 2024
- Manual Googling: Nov 02, 2024
- iThenticate Software: Nov 09, 2024 (15%)

**ETYMOLOGY:** Author Origin**EMENDATIONS:** 6**AUTHOR DECLARATION:**

- Financial or Other Competing Interests: None
- Was informed consent obtained from the subjects involved in the study? Yes
- For any images presented appropriate consent has been obtained from the subjects. Yes

Date of Submission: **Aug 27, 2024**Date of Peer Review: **Sep 26, 2024**Date of Acceptance: **Nov 11, 2024**Date of Publishing: **Jan 01, 2025**